

The Correlation Between Clinical And Pathological Lymph Node Status In Oral Squamous Cell Carcinoma

Nimisha Priya^{1*}, Abani Kanta Nanda², Anusuya Mishra³, Ruchika Chaudhary⁴, Varun Kashyap⁵, Azmi Malik⁶

^{1*}Department of Dentistry, Jawaharlal Nehru Medical College and Hospital, Bhagalpur

²Radiation Oncologist, Acharya Harihar Post Graduate Institute of Cancer, Cuttack

³Department of Pedodontics and Preventive Dentistry, S.C.B Dental College and Hospital, Cuttack

⁴Assistant Professor, Department of Oral Medicine and Radiology, Government Dental College, Jodhpur

⁵Senior Lecturer, Department of Oral and Maxillofacial Surgeon, Daswani Dental College, Kota

⁶Senior Lecturer, Department of Oral Medicine and Radiology, Dental College Azamgarh, Azamgarh

Corresponding Author- Nimisha Priya
priyanimisha1993@gmail.com

Keywords	Abstract
Lymph Node, Metastasis, Oral Cancers.	<p>Background: The most significant factor affecting the prognosis of oral malignancies is lymph node metastasis; the existence of malignant lymph nodes reduces survival by 50%.</p> <p>Methodology: every person with oral cancer had contrast-enhanced CECT of the neck and oral cavity after becoming initially evaluated for enlarging neck node. Following neck dissection, all lymph node levels were evaluated histopathologically, and all node features were documented in CECT.</p> <p>Results: Of the 24 individuals in our investigation, 31 had clinically observed enlarged lymph nodes. A total of 90 enlarged lymph nodes, including 21 positive nodes, were detected by CECT. Only thirty-two of the 538 lymph nodes that were isolated in histopathology tested positive for malignancy.</p> <p>Conclusions: The detection rate of enlarged lymph nodes is more with histopathology than radiological and clinical examination. In our study, 94% of lymph node enlargement was proven to be reactive, which shows more tumor-associated inflammation.</p>

Introduction

In India, cancer of the head and neck is a very common occurrence. The most frequent kind of head and neck cancer is oral cancer. Among the greatest significant variables affecting the prognosis of oral malignancies is lymph nodes metastases. If there are cancerous lymph nodes in the neck, the survival rate will decrease by almost 50%.¹ In accordance with current study, there is tumour related inflammation around the tumor. Tumor-associated inflammatory is primarily responsible for the expansion of lymph nodes in mouth malignancies. Clinically, neck nodes can only be felt when they are 1.5 cm in length; however, an ultrasound can identify lymphatic nodes as small as 5 mm, and a CT scan can identify lymph nodes as large as 2 mm.^{2,3}

In oral cancers, most of the lymph nodes which were enlarged are mostly reactive than metastatic. This study is destined to detect enlarged reactive and positive nodes clinically, radiologically, and pathologically. This study also correlates between clinical and pathological lymph node status in oral squamous cell carcinoma.

Methodology

This investigation progressive observational one. Every aspect individuals visiting Dental OPD, at Jawaharlal Nehru Medical College and Hospital, Bhagalpur with histologically established oral cancer were incorporated in course of this research. Featured were all surgically operated on individuals with histologically confirmed tumours in the mouth who had clinically evident expanded lymph nodes. Post radiotherapy and post neoadjuvant chemotherapy were excluded. Such individuals were checked clinically for swollen neck nodes. Every detail pertaining to the patient, tumour, and nodes—including their level, size, number, coherence, mobility, and skin covering—was documented. The patient was subjected to CECT oral cavity and biopsy from the primary lesions.

In CECT, all the characteristics of nodes, i.e., number, levels, size, presence, and absence of fatty hilum, enhancing characteristics, necrotic status matted/discrete, surrounding soft tissue involvement were noted. If required, pre-operative FNAC of lymph node swelling was performed to plan surgery, such as when a contralateral lymph node was present to figure out if it was reactive or positive for malignancy, or when multiple tumour biopsies were performed and the results were negative. The patient was posted for surgery, and during neck dissection, all the levels of lymph nodes were dissected separately and sent for histopathology. The pathologist divided the reactive and positive nodes according to levels and assessed for extracapsular spread. All the clinical, radiological, and histological findings will be correlated and analysed. The software used for statistical analysis was SPSS version 23.

Results

In the study, 24 patients were included, among which 20 were females, and 4 were males. Among which two patients were 30 to 40 years age group, eight patients were 41 to 50 years age group; eight patients were 51 to 60 years age group, four patients were 61-70 years age group and two patients were 71 to 80 years age group.

Table 1: The correlation of nodal staging between clinical, radiological and histopathological findings.

Nodal staging	Clinical		Radiological		Histopathological	
	N	%	N	%	N	%
N0	1	4.17	1	4.17	16	66.7
N1	12	50	0	0	5	20.8
N2a	1	4.17	0	0	0	0
N2b	6	25	19	79.17	2	8.3
N2c	3	12.5	4	16.7	0	0
N3a/b	1	4.17	0	0	1	4.17

Table 2: The number of lymph nodes according to levels clinically, radiologically and histopathologically

Levels	Clinical		Radiological		Pathological	
	N	%	N	%	N	%
Ia	0	0	10	11.1	4	12.1
Ib	30	96.7	40	44.4	11	33.3
II	0	0	26	28.9	9	27.2
III	0	0	6	6.7	2	6
IV	0	0	3	3.3	0	0
V	1	3.2	5	5.5	7	21.2

Clinically

Figure 1- Clinical diagnosis of the subjects included in the study.

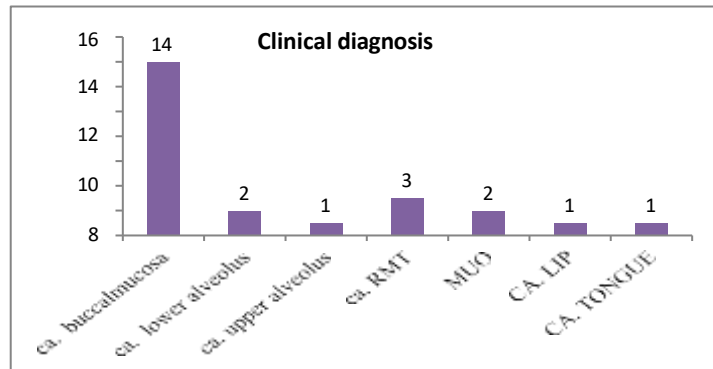
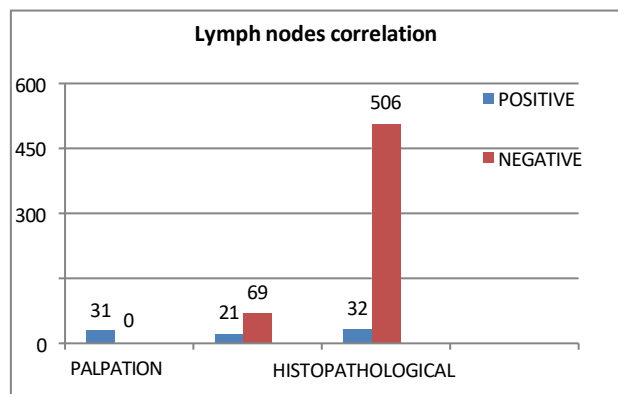


Figure 2: Correlation of clinical, radiological and histopathologically positive and negative lymph nodes.



Radiologically

Totally 90 lymph nodes were detected on CECT neck in all 24 patients. Among them ten lymph nodes were found A total of 538 lymph nodes were detected in the histopathological examination after 25 neck dissections in 24 patients (1 case bilateral neck dissection). Among 25 neck dissections, 24 modified radical neck dissections and one supra-omohyoid neck dissection were done. Among them, 33 were found positive for malignancy in only eight patients with rest 16 patients had only reactive nodes. Totally five lymph nodes had extracapsular spread. Positive lymph nodes were found in level 1a-4, level 1b-11, level II-9, level III-2, level IV-0, level V-7.

Discussion

Head and neck cancer is a very common entity encountered in India.¹ More than 90% of these carcinomas are found to be squamous cell carcinoma, where treatment options include mainly surgery, radiotherapy, and/or chemotherapy. Lymphogenic metastasis represents the most important prognostic factor for squamous cell carcinoma of the upper aerodigestive tract. Presence of lymph node metastasis is associated with 50% reduction in survival rate.²

In our study, the majority of the patients were females with male: female ratio of 1:5, and most of them belonged to the 4th and 5th decade. In a study by Mehta et al, 70% were males, and most of the patients were in the 3rd and 5th decade.³ In another study by Essig et al, also had 75% of male patients with a male:female ratio of 3:1 and majority of the patients was found at 5th decade of life.²

Clinical palpation is the basic method in evaluating metastatic cervical lymph nodes.^{4,5} The high sensitivity of palpation is credited to the physical characteristics such as size and consistency. In our study, the majority of the cases were maximum of T4a and under stage IVa. A similar study had the majority of the cases from T2 group were 45.7%, followed by T4 that is 32.85% and T3 that is 21.4%.² In our study majority of the cases were of N1 where a study by Czembireck et al had staged 67% of patient in N2a, N2b, N2c.⁶

Radiologically we have 23.3% of positive lymph nodes out of total 90 lymph nodes detected from CECT. The lymph node characteristics of a positive node radiologically include short-axis diameter >1 cm, the ratio of long axis to short-axis diameter <2 cms, absence of fatty hilum, round appearance, rim enhancement, central necrosis.⁷ According to Som, minimum size of lymph nodes at submandibular space considered to be metastatic is 15 mm while for other regional lymph nodes is 10 mm. Presence of conglomerated, more than one lymph node, extranodal involvement, irregular contours, central necrosis, and capsular invasion are criteria for nodal metastasis on CT. Lima bean-shaped node is considered hyperplastic while round indicates neoplastic infiltration.⁹ These similar criteria were further explained by Sarvannan et al and found CT sensitivity and specificity of 95.65% and 66.65% with accuracy of 92.30%, while the conglomeration and central necrosis had sensitivity and specificity of 100% thus increasing its accuracy in detection of cervical metastasis.⁴ Feinmesser et al stated in there finding that CT, when compared with clinical evaluation, has slightly lower predictive value of 81.6% and sensitivity of 59.6% which is also low, so indicating chances of high false-negative rate. Correct diagnosis on CT is 59.6% with the proved pathologic disease.⁸

Conclusion

There was a gross disparity between clinical, radiological, and histological assessment in the number of reactive and positive lymph nodes. This study shows more tumor-associated inflammation leading to reactive lymph nodes than metastatic lymph nodes.

References

1. Mishra A, Meherotra R. Head and neck cancer: global burden and regional trends in India. *Asian Pac J Cancer Prev.* 2014;15(2):537-50.
2. Essig H, Warraich R, Zulfiqar G, Rana M, Eckardt AM, Gellrich NC, Rana M. Assessment of cervical lymph node metastasis for therapeutic decisionmaking in squamous cell carcinoma of buccal mucosa: a prospective clinical analysis. *World J Surg Oncol.* 2012;10:253-9.
3. Mehta N, Sharma R, Madhok R, Agrawal T, Sharma V. A Clinical, Radiological, and Histopathological Correlation of Neck Nodes in Patients Undergoing Neck Dissection. *Int J Appl Basic Med Res.* 2018;8(1):9-13.
4. Sarvannan K, Bapuraj JR, Sharma SC, Radotra BD, Khandelwal N, Suri S. Computed tomography and ultrasonographic evaluation of metastatic cervical lymph nodes with surgicoclinicopathologic correlation. *J Laryngol Otol.* 2002;116(3):194-9.
5. August M, Nguyen M. Evaluation of metastatic neck disease by computed tomography. *Int J Oral Maxillofac Surg.* 1994;23(5):290-3.
6. Eder-Czembirek C, Erlacher B, Thurnher D, Erovic BM, Selzer E, Formanek M. Comparative Analysis of Clinical and Pathological Lymph Node Staging Data in Head and Neck Squamous Cell Carcinoma Patients Treated at the General Hospital Vienna. *Radiol Oncol.* 2018;52(2):173-80.
7. Van den Brekel MW, Castelijns JA, Snow GB. Diagnostic evaluation of the neck. *Otolaryngology Clin North Am.* 1998;31(4):601-20.
8. Feinmesser R, Freeman JL, Noyek AM, Birt D, Gullane P, Mullen JB. MRI and neck metastases: a clinical, radiological, pathological correlative study. *J Otolaryngol.* 1990;19(2):136-40.
9. Som PM. Detection of metastasis in cervical lymph nodes: CT and MR criteria and differential diagnosis. *AJR Am J Roentgenol.* 1992;158(5):961-9.